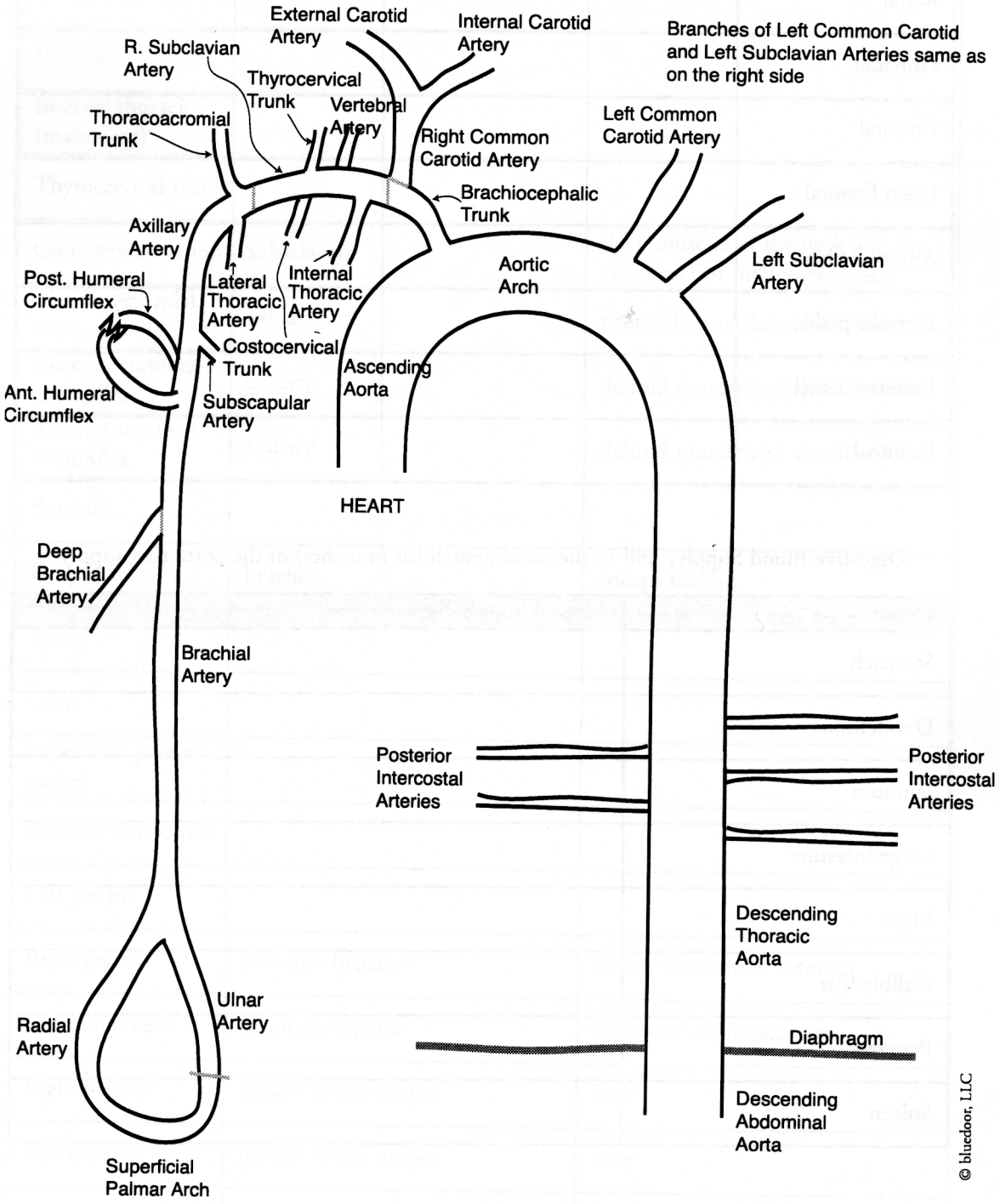
External Carotid Artery
Internal Carotid Artery
Branches of Left Common Carotid and Left Subclavian Arteries same as on the right side
R. Subclavian Artery
Thyrocervical Trunk
Vertebral Artery
Thoracoacromial Trunk
Left Common Carotid Artery
Right Common Carotid Artery
Brachiocephalic Trunk
Axillary Artery
Aortic Arch
Left Subclavian Artery
Post. Humeral Circumflex
Lateral Thoracic Artery
Internal Thoracic Artery
Costocervical Trunk
Ascending Aorta
Ant. Humeral Circumflex
Subscapular Artery
HEART
Deep Brachial Artery
Brachial Artery
Posterior Intercostal Arteries
Posterior Intercostal Arteries
Descending Thoracic Aorta
Ulnar Artery
Radial Artery
Diaphragm
Descending Abdominal Aorta
Superficial Palmar Arch
© bluedoor, LLC